IHC enhanced validation of Anti-VISTA rabbit monoclonal antibody [EPR21050] – ab230950

IHC enhanced validation data pack

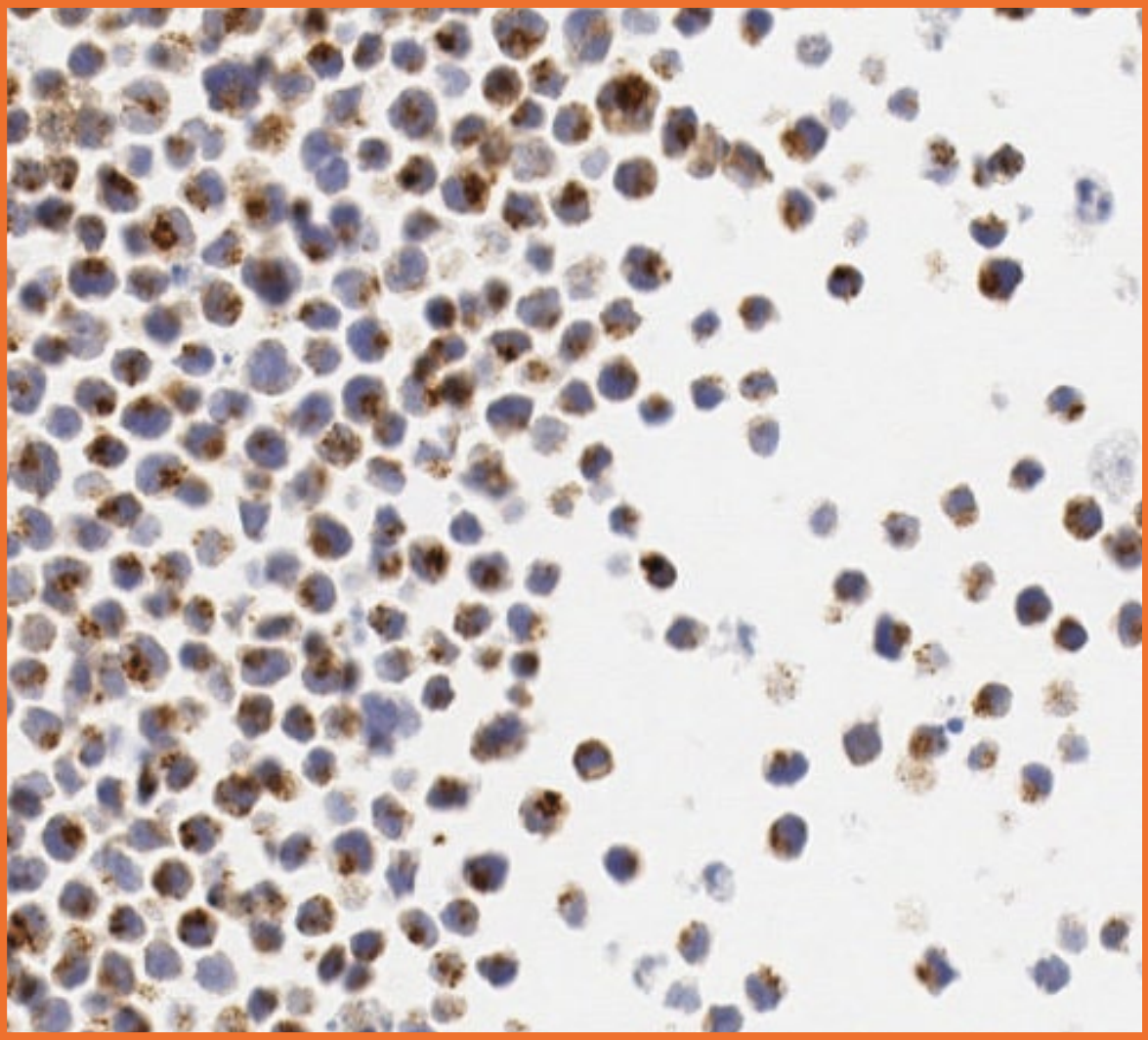

AB0266_v2.0_090525

progress happens together

abcam

IHC enhanced validation of Anti-VISTA rabbit monoclonal antibody [EPR21050] – ab230950

Overview of enhanced validation

— An optimized protocol for IHC testing of Anti-VISTA rabbit monoclonal antibody [EPR21050] – ab230950 on a BOND™ RX Research Stainer (Leica®) has been developed.

— Antibody specificity was evaluated using cell lines, multi-normal and multi-tumor human tissue microarray (TMA).

— Antibody sensitivity was evaluated using human cancer TMAs containing a mix of cases, cancer subtypes and tumor grading.

Target overview

Function
An immunoregulatory receptor that inhibits the T-cell response.

Sequence similarities
Contains 1 Ig-like (immunoglobulin-like) domain.

Cellular localization
Membrane.

Normal tissue expression
Membrane staining is expected in either hematopoietic tissues (ie, spleen, lymph nodes, peripheral blood) or those tissues with significant infiltration by leukocytes.[1]

Cancer expression
Cancer tissues are expected to have membrane/cytoplasmic expression of tumor cells and membrane staining of tumor-infiltrating T cells.[2-4]

Target information above from: UniProt accession Q9H7M9
The UniProt Consortium
The Universal Protein Resource (UniProt) in 2010
Nucleic Acids Res. 38:D142-D148 (2010).

References

1. Lines JL, Pantazi E, Mak J, et al. VISTA is an immune checkpoint molecule for human T cells. *Cancer Res*. **74**(7):1924-32 (2014).
2. Zhang M, Pang HJ, Zhao W, et al. VISTA expression associated with CD8 confers a favorable immune microenvironment and better overall survival in hepatocellular carcinoma. *BMC Cancer*. **18**(1):511 (2018).
3. Mulati K, Hamanishi J, Matsumura N, et al. VISTA expressed in tumour cells regulates T cell function. *Br J Cancer*. **120**(1):115-127 (2019).
4. Böger C, Behrens HM, Krüger S, Röcken C. The novel negative checkpoint regulator VISTA is expressed in gastric carcinoma and associated with PD-L1/PD-1: A future perspective for a combined gastric cancer therapy? *Oncoimmunology*. **6**(4):e1293215 (2017).

AB0266_v2.0_090525

IHC staining protocol: BOND™ RX Research Stainer (Leica®)

Prestaining protocol		
Step	**Reagents**	**Pre-programmed protocol**
Dewax	BOND™ dewax solution (#AR922), alcohol, BOND wash solution (#AR9590)	Prestaining protocol: Dewax
Antigen retrival	BOND™ epitope retrieval ER2 solution (#AR9640)	Prestaining protocol: HIER with ER2, 20 min, 98°C

Staining protocol				
Step	**Reagents**	**Number of washes**	**Incubation time, min**	**Temperature**
Wash	BOND™ wash solution	3x	0	Ambient
Primary antibody	Anti-VISTA rabbit monoclonal antibody (EPR21050) – ab230950 Diluted in BOND™ primary antibody diluent (#AR93523) to final concentration of 0.5 µg/mL (FFPE Tissue)	-	15	
Wash	BOND™ wash solution	3x	0	
Secondary detection	Refine detection kit - polymer (#DS0900)	-	8	
Wash	BOND™ wash solution	2x	0	
	Deionized water	1x	0	
Visualization	Refine detection kit - mixed DAB refine (#DS0900)	1x	10	
Wash	Deionized water	3x	0	
Counterstain	Refine detection kit - hematoxylin (#DS0900)	-	5	
Wash	Deionized water	1x	0	
	BOND™ wash solution	1x	0	
	Deionized water	1x	0	

Leica® is a registered trademark of Leica Microsystems IR GmbH. BOND™ and BOND™ RX are trademarks of Leica Biosystems Melbourne Pty. Ltd

AB0266_v2.0_090525

Materials

Human Cell Lines		
Cell Line	**Disease**	**Source**
U-937	Histiocytic Lymphoma	Abcam
A549	Lung carcinoma	Abcam
Hep G2	Hepatocellular carcinoma	Abcam
MCF7	Breast adenocarcinoma	Abcam

Human Normal Tissue			
Tissue Micro Array	**Tissue Sites**	**Core Replicates**	**Source**
Human Normal	12	3	Abcam

Human Cancer Tissue						
Tissue Micro Array	**Cores**	**Cases**	**Normal/ Benign Cases**	**Cancer Cases**	**Source (#catalog number)**	**Map**
Lung cancer	160	80	3	77	Pantomics (#LUC1021)	Link
Colorectal cancer	102	102	5	97	Pantomics (#REC1021)	Link
Liver cancer	102	102	5	97	Pantomics (#LVC1021)	Link
Endometrial cancer	102	102	5	97	Pantomics (#EMC1021)	Link

AB0266_v2.0_090525

FFPE cell pellet images

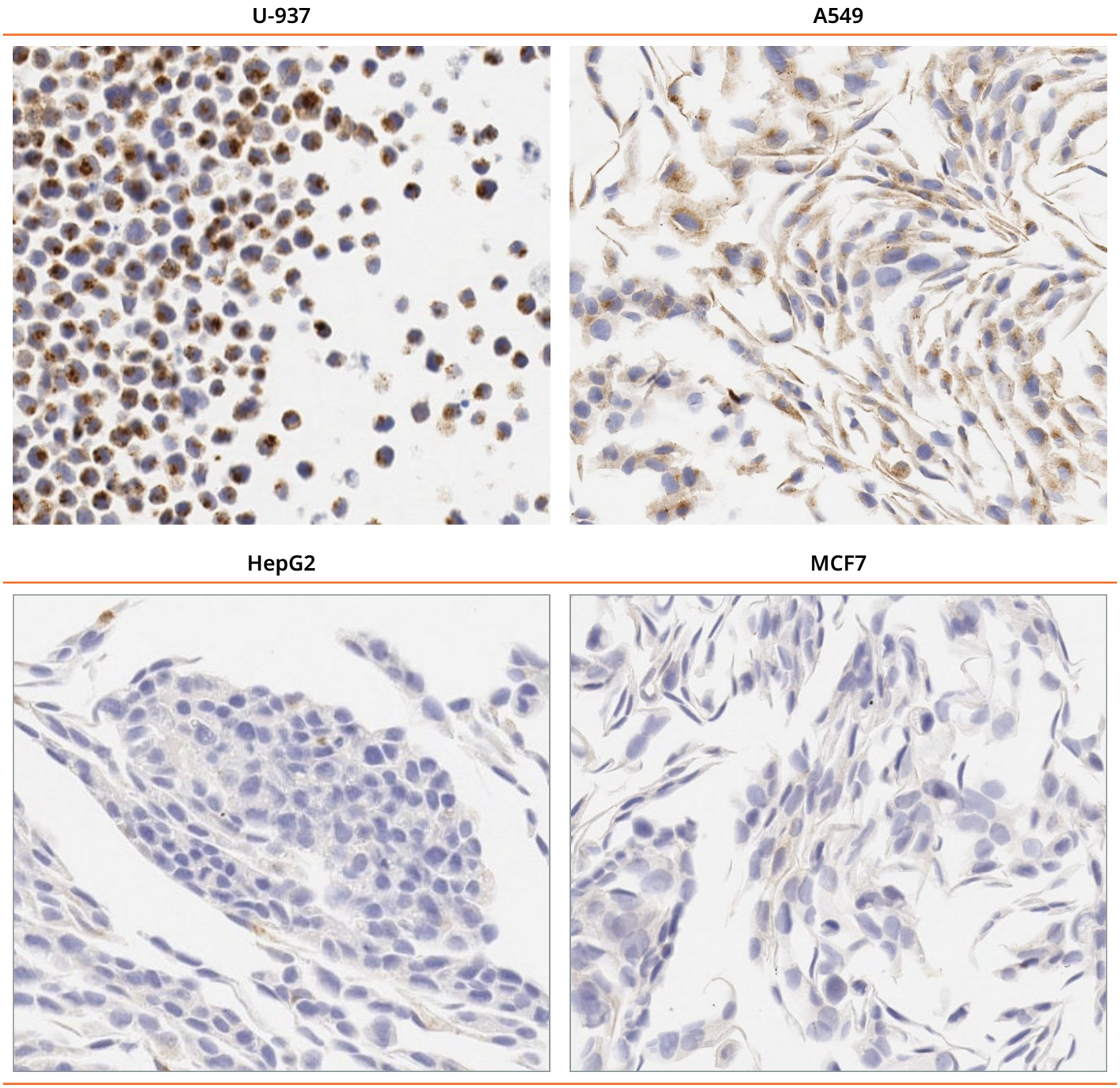

Figure 1

Representative IHC images show VISTA expression was detected in the cytoplasm of U-937 and A549 cell lines (positive control) and absent from HepG2 and MCF7 cell lines (negative control). IHC staining of FFPE cell pellets was performed using anti-VISTA (ab230950) at a final concentration of 0.5 µg/mL. The omission of the primary antibody demonstrated no background staining from the secondary detection kit (data not shown). Positive staining in brown; hematoxylin counterstain in blue. Magnification, x20.

AB0266_v2.0_090525

Human normal TMA images

Skeletal muscle

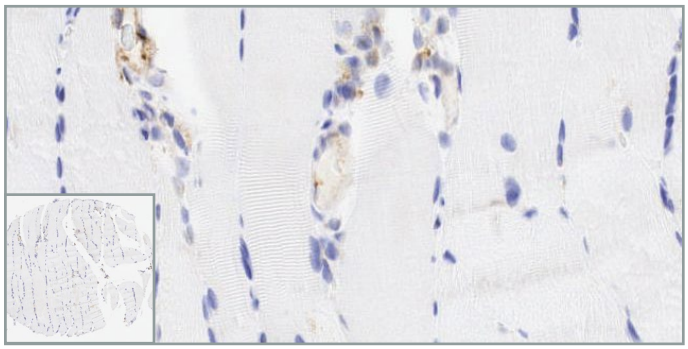

Colon

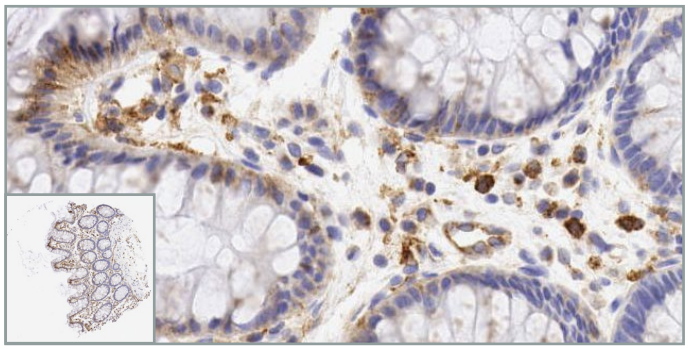

Duodenum

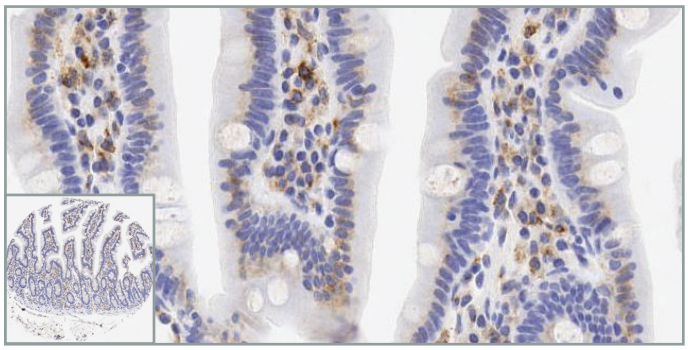

Stomach

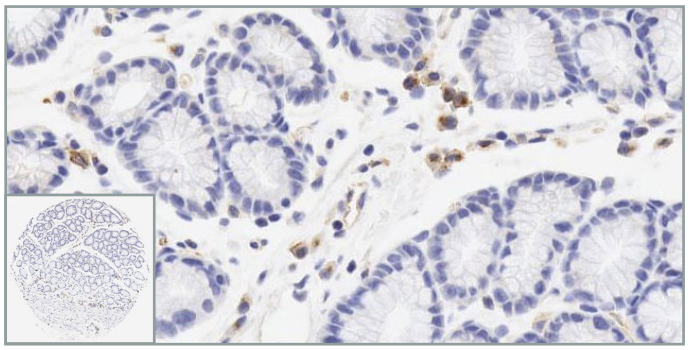

Heart

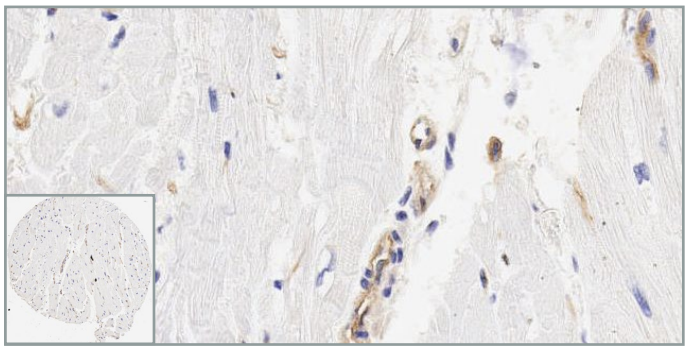

Liver

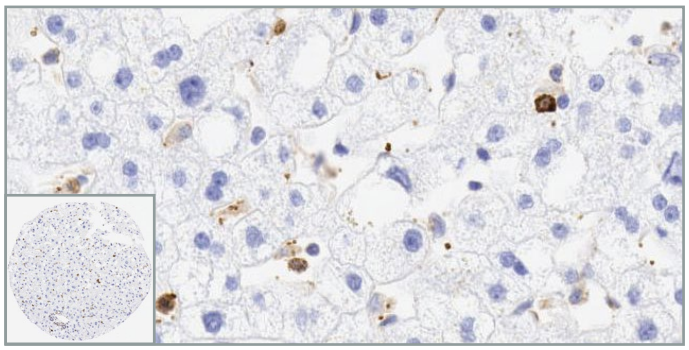

Lung

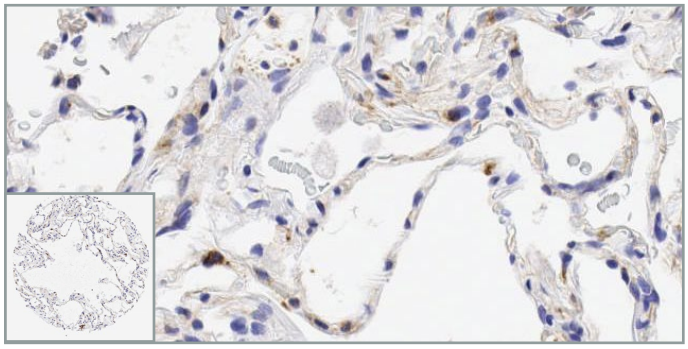

Pancreas

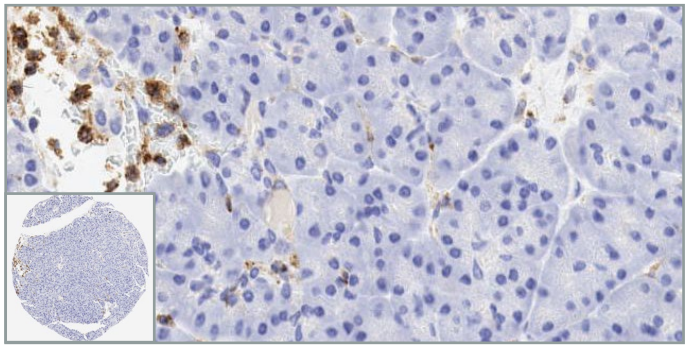

AB0266_v2.0_090525

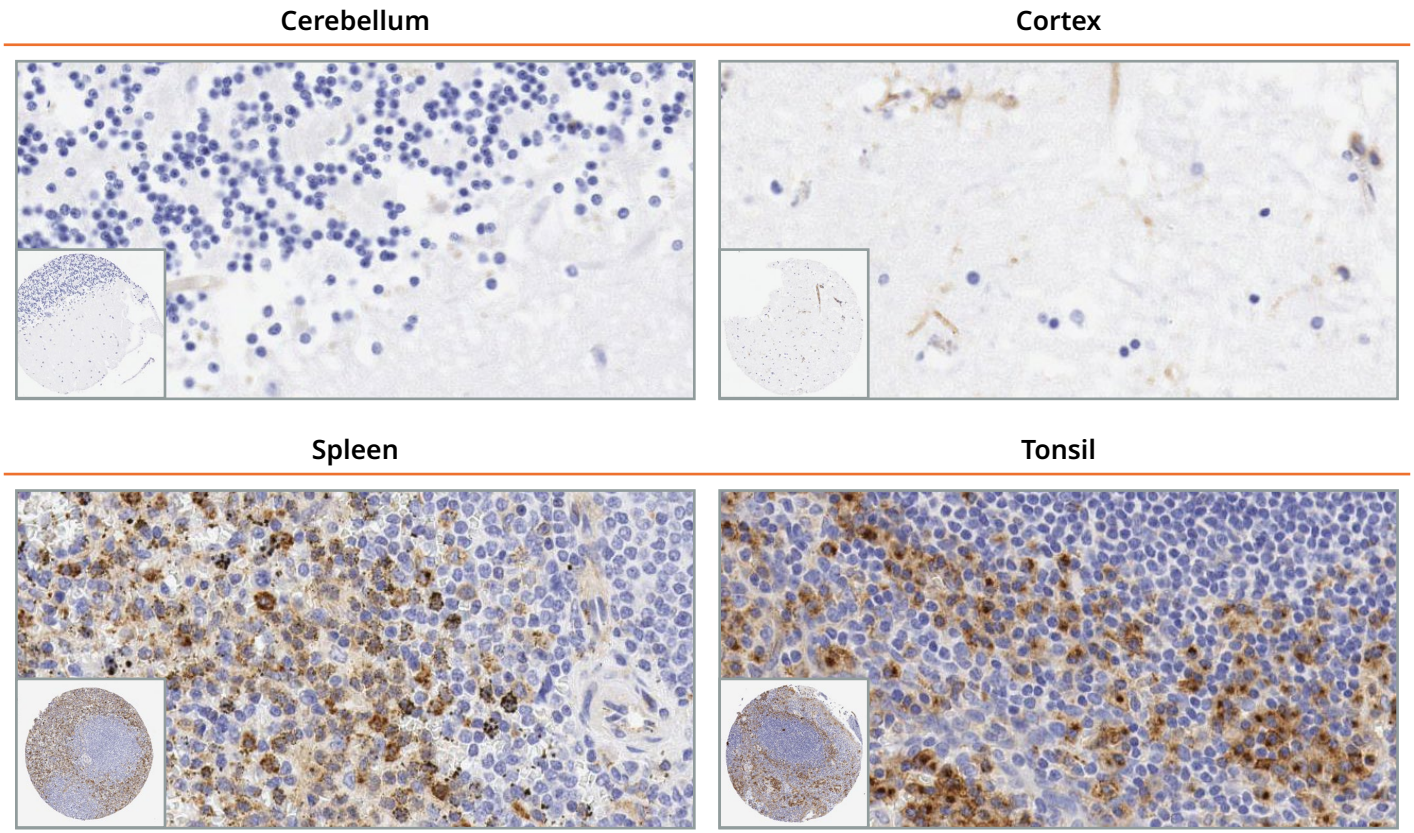

Figure 2

VISTA expression in human normal tissue. IHC staining of human normal TMAs was performed using anti-VISTA (ab230950) at a final concentration of 0.5 µg/mL. The omission of the primary antibody demonstrated no background staining from the secondary detection kit (data not shown). Positive staining in brown; hematoxylin counterstain in blue. Magnification, x20.

Lung cancer TMA

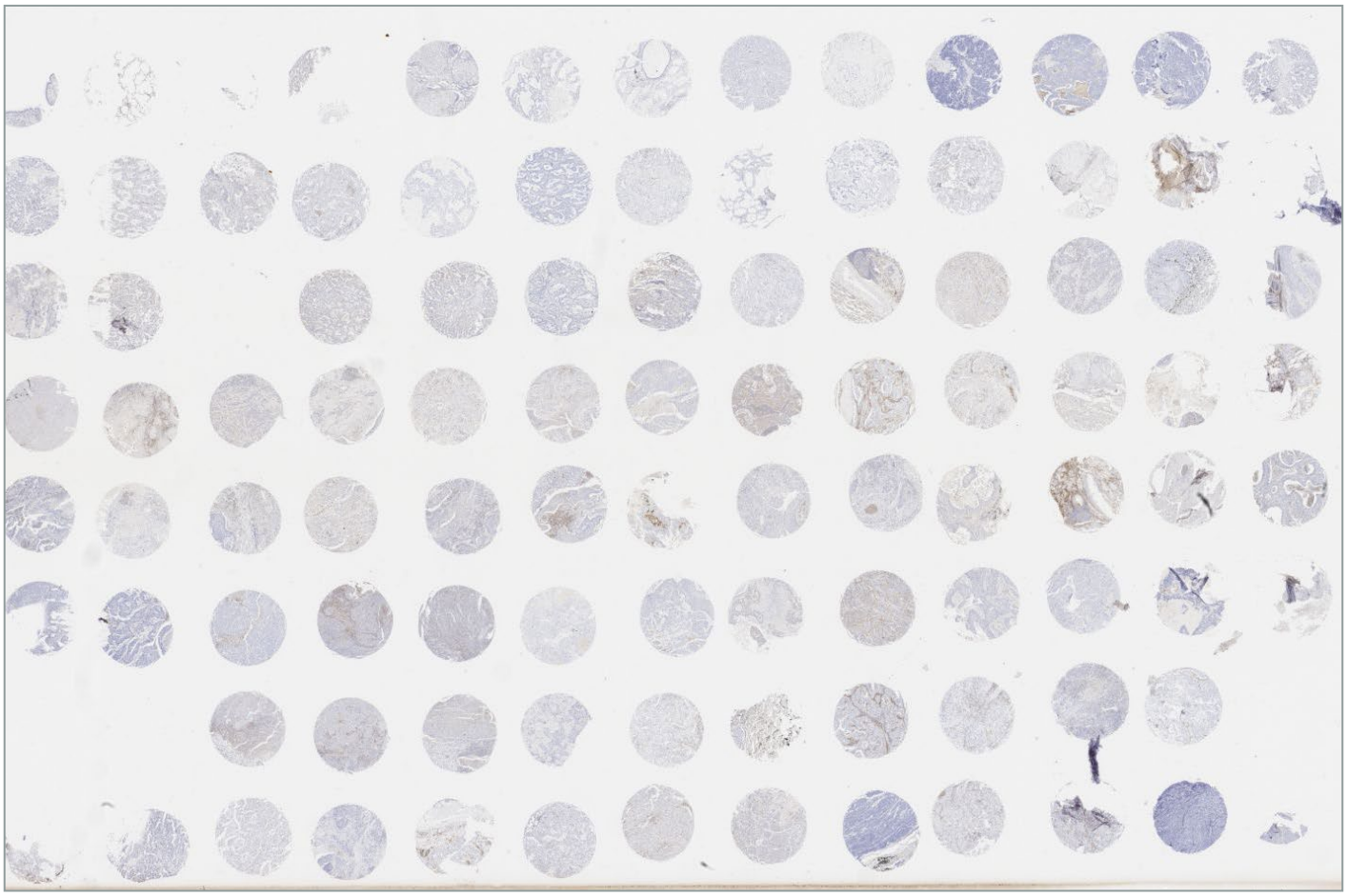

Figure 3

VISTA expression in lung cancer. IHC staining of a human lung cancer TMA (Pantomics #LUC1021), using anti-VISTA (ab230950) at a final concentration of 0.5 µg/mL. Pathological lung cancer subtypes included within TMA; normal (3 cases), adenocarcinoma (17 cases), adenosquamous carcinoma (9 cases), bronchioloalveolar carcinoma (11 cases), carcinoid (1 case), clear cell carcinoma (1 case), small cell carcinoma (3 cases), squamous cell carcinoma (49 cases), tuberculosis, TB granuloma (2 cases), undifferentiated carcinoma (4 cases), undifferentiated carcinoma, large cell (1 case). Positive staining in brown; hematoxylin counterstain in blue. Magnification, x0.6.

AB0266_v2.0_090525

Representative IHC images of lung cancer TMA

Adenocarcinoma (0)

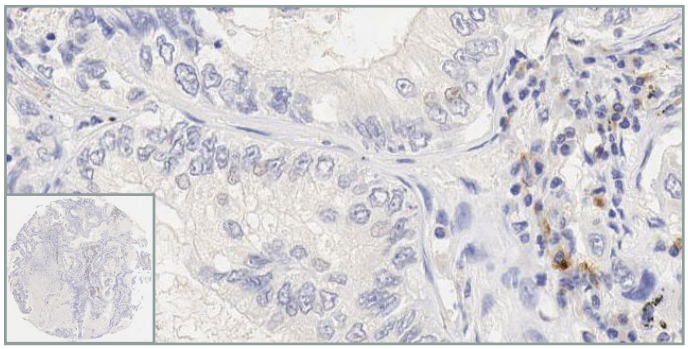

Adenocarcinoma (0.5+)

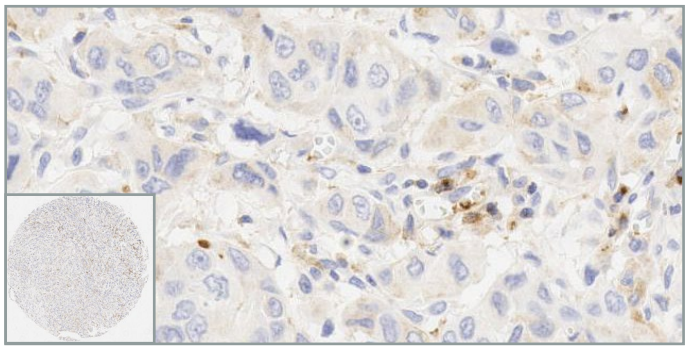

Adenosquamous carcinoma (0)

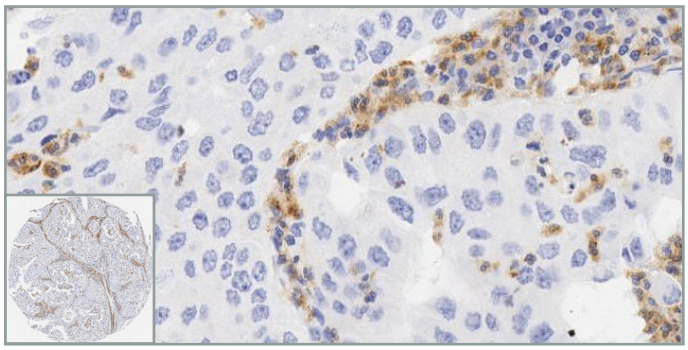

Adenosquamous carcinoma (0.5+)

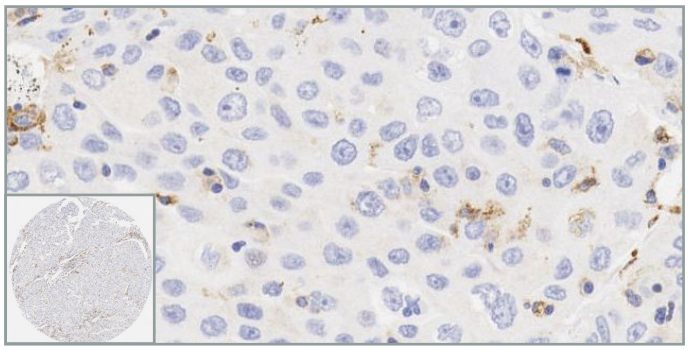

Bronchioloalveolar carcinoma (0)

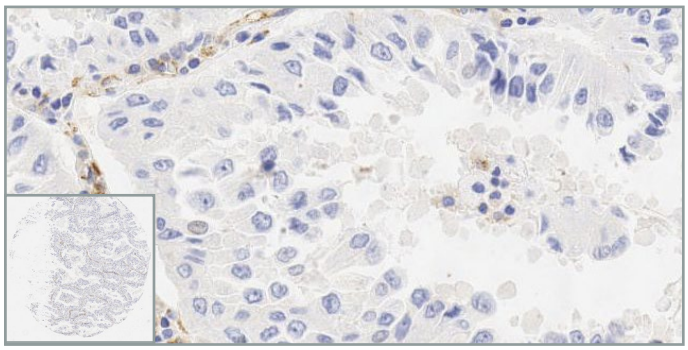

Carcinoid (0)

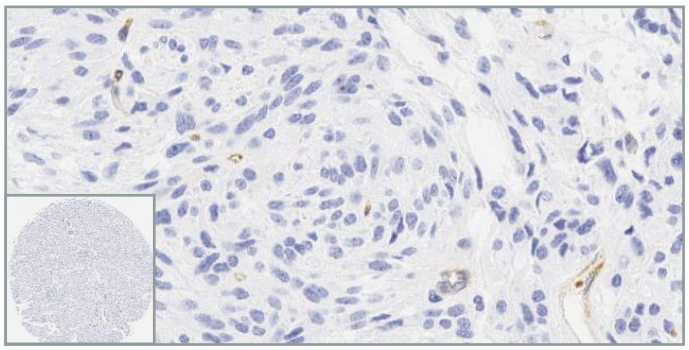

Clear cell carcinoma (0)

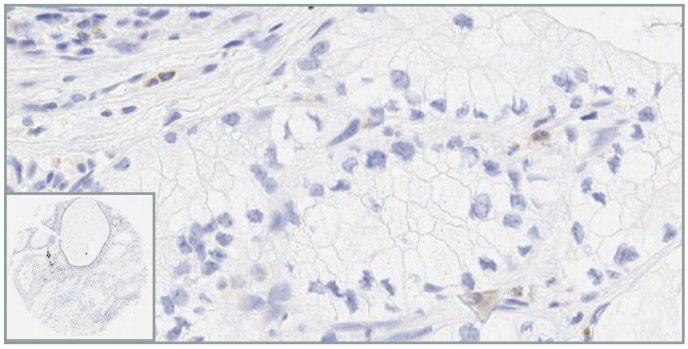

Small cell carcinoma (0)

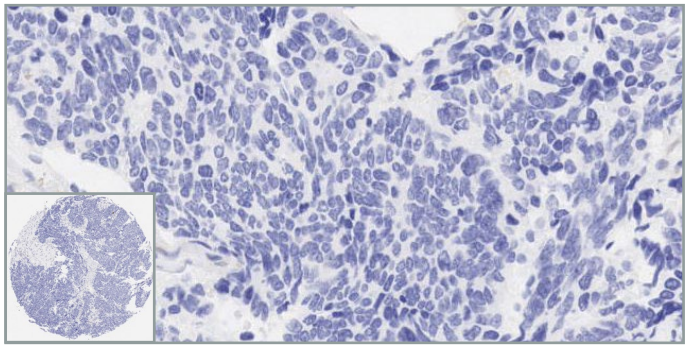

AB0266_v2.0_090525

Squamous cell carcinoma (2+)

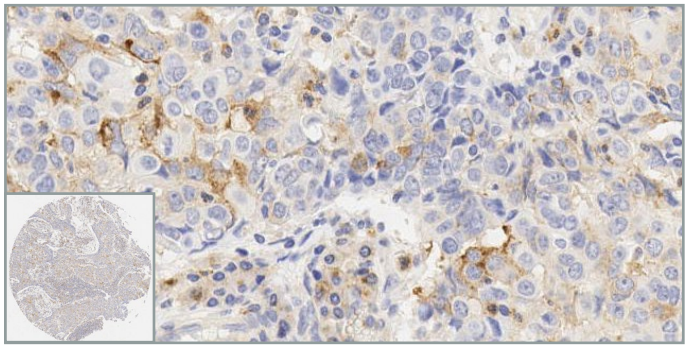

Squamous cell carcinoma (1+)

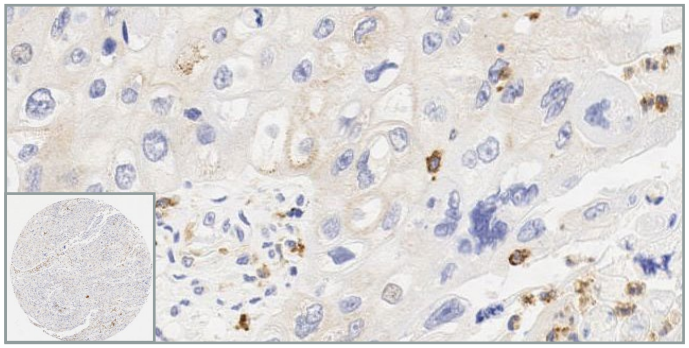

Squamous cell carcinoma (0)

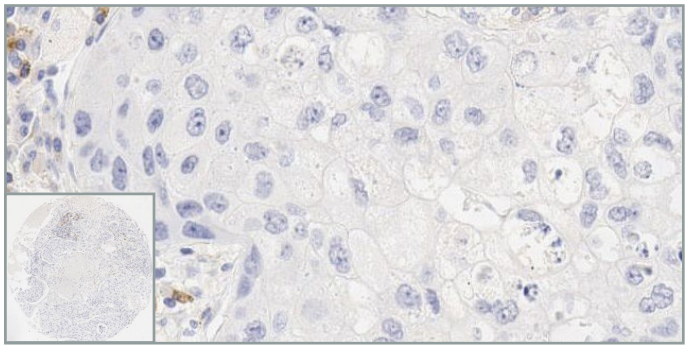

Tuberculosis, TB granuloma (0.5+)

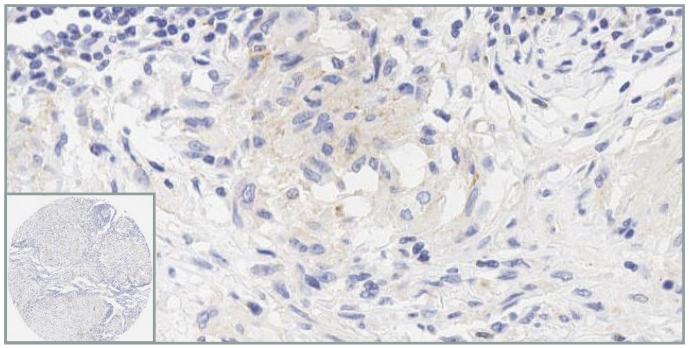

Undifferentiated carcinoma (1+)

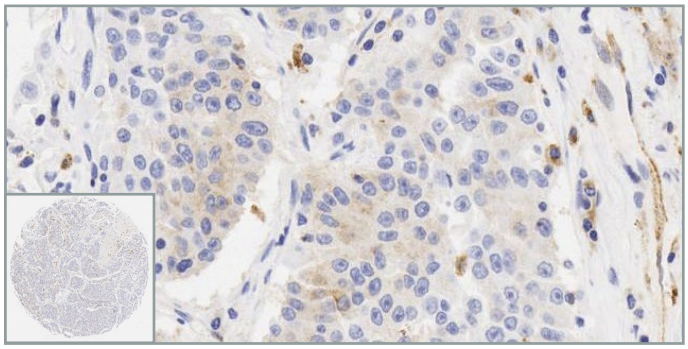

Undifferentiated carcinoma (0)

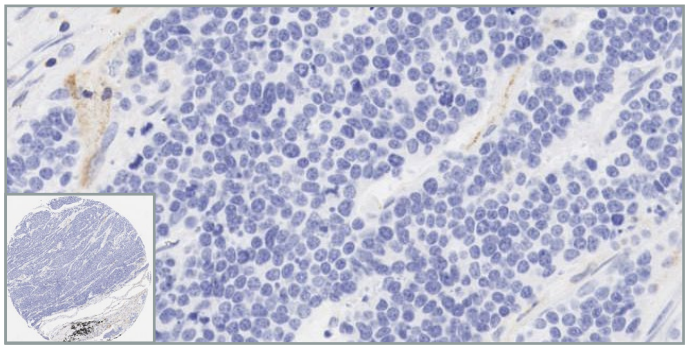

Undifferentiated carcinoma, large cell (0)

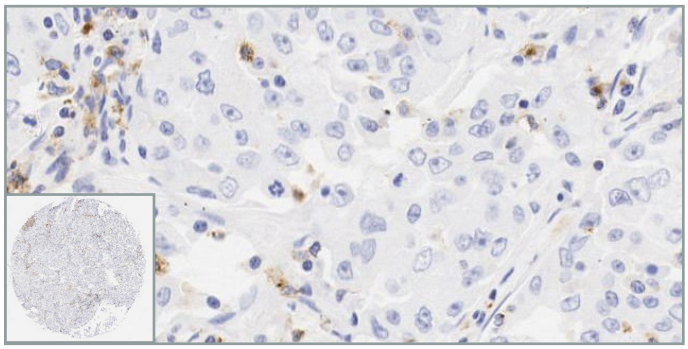

Figure 4

VISTA expression intensity in lung cancer. Semi-quantitative scoring of the average tumor expression intensity (0-3+, with a 0.5 interval) was performed by eye. Representative images show VISTA expression intensity observed in each pathological cancer subtype. Positive staining in brown; hematoxylin counterstain in blue. Magnification, x5 and x20.

AB0266_v2.0_090525

Colorectal cancer TMA

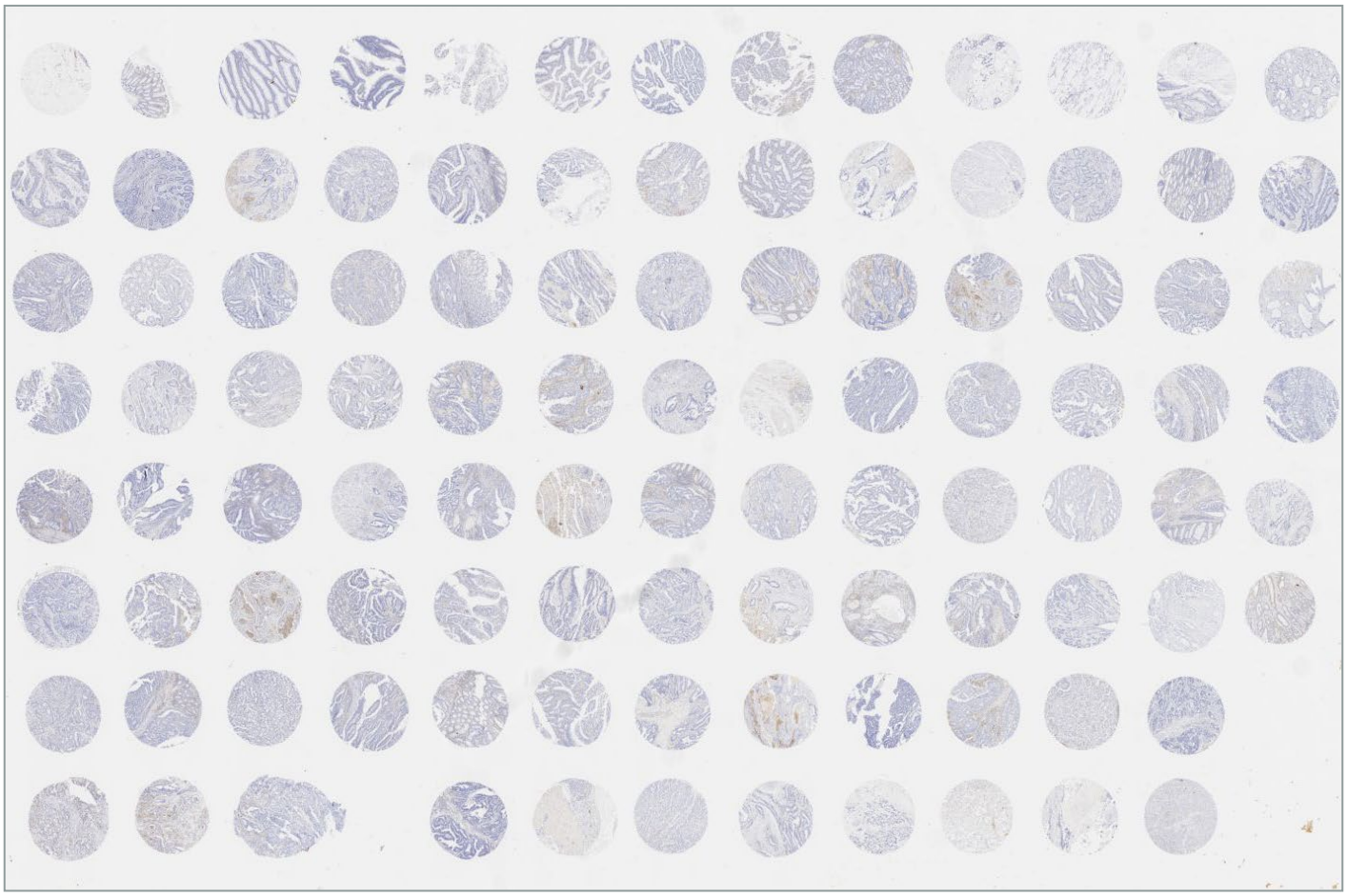

Figure 5

VISTA expression in colorectal cancer. IHC staining of a human colorectal cancer TMA (Pantomics #REC1021), using anti-VISTA (ab230950) at a final concentration of 0.5 µg/mL. Pathological colorectal cancer subtypes included within TMA; normal (2 cases), adenocarcinoma (89 cases), mucinous adenocarcinoma (3 cases), papillary adenocarcinoma (4 cases), undifferentiated carcinoma (1 case), villous adenoma (3 cases). Positive staining in brown; hematoxylin counterstain in blue. Magnification, x0.6.

AB0266_v2.0_090525

Representative IHC images of colorectal cancer TMA

Adenocarcinoma (2+)

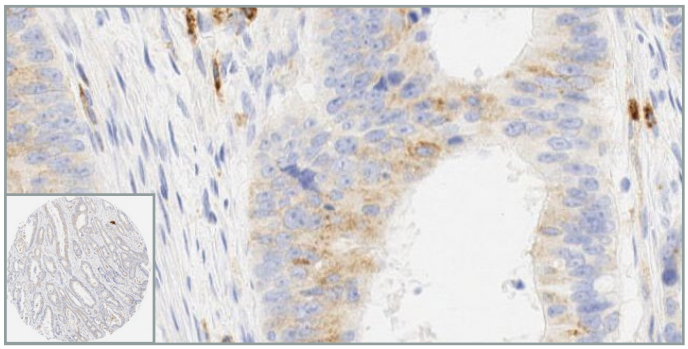

Adenocarcinoma (1+)

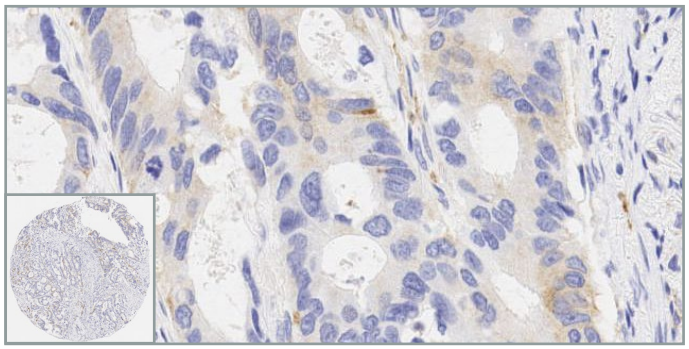

Adenocarcinoma (0.5+)

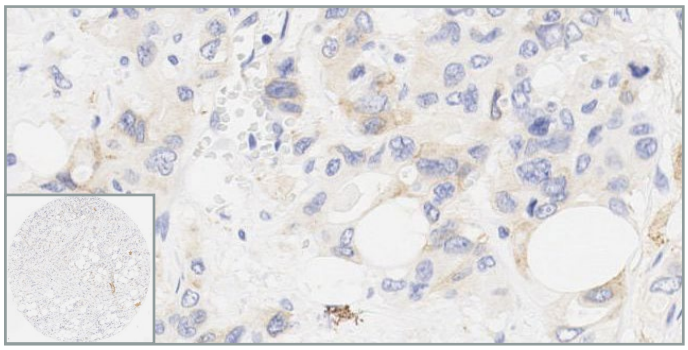

Adenocarcinoma (0)

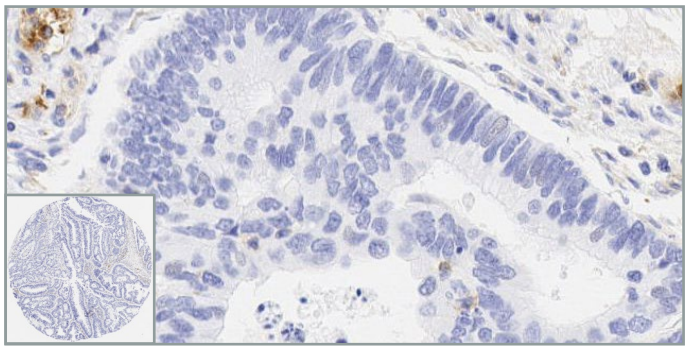

Mucinous adenocarcinoma (0)

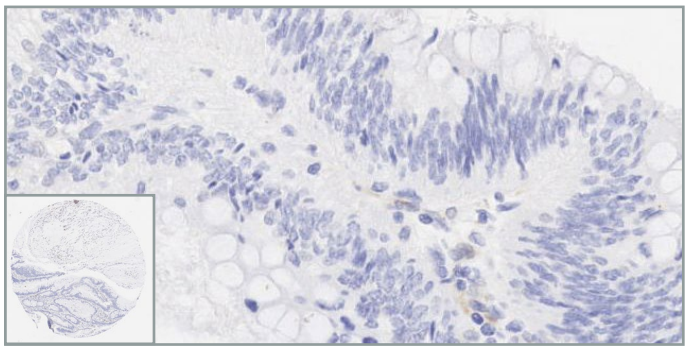

Papillary adenocarcinoma (1+)

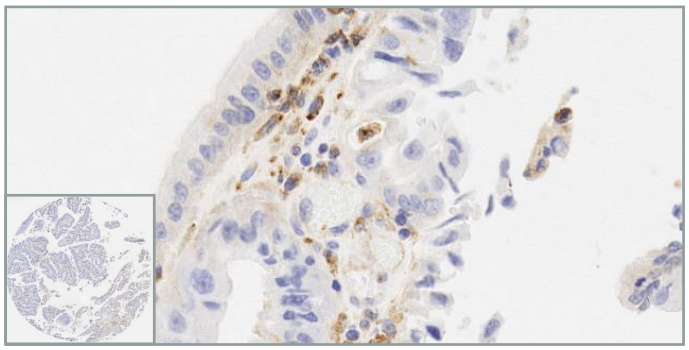

Papillary adenocarcinoma (0)

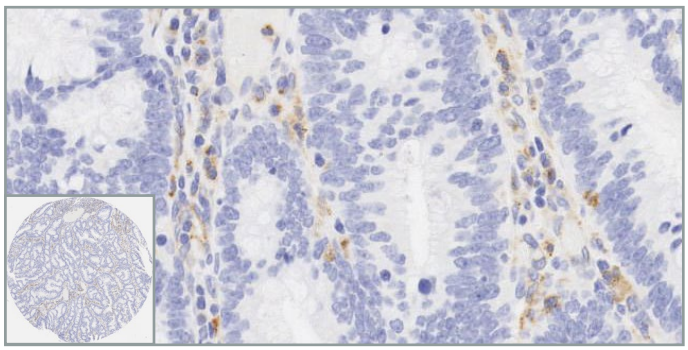

Undifferentiated carcinoma (0)

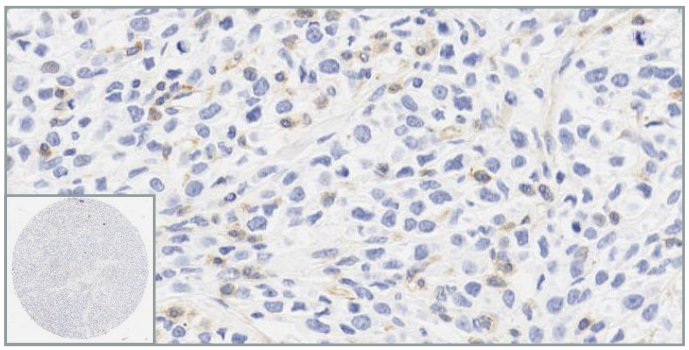

AB0266_v2.0_090525

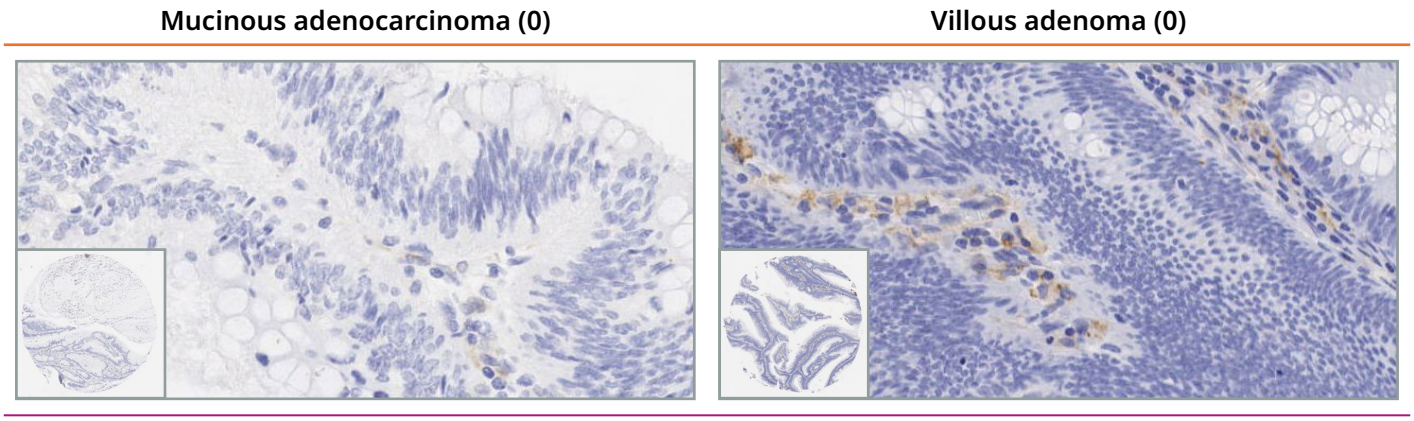

Figure 6

VISTA expression intensity in colorectal cancer. Semi-quantitative scoring of the average tumor expression intensity (0-3+, with a 0.5 interval) was performed by eye. Representative images show VISTA expression intensity observed in each pathological cancer subtype. Positive staining in brown; hematoxylin counterstain in blue. Magnification, x5 and x20.

AB0266_v2.0_090525

Endometrial cancer TMA

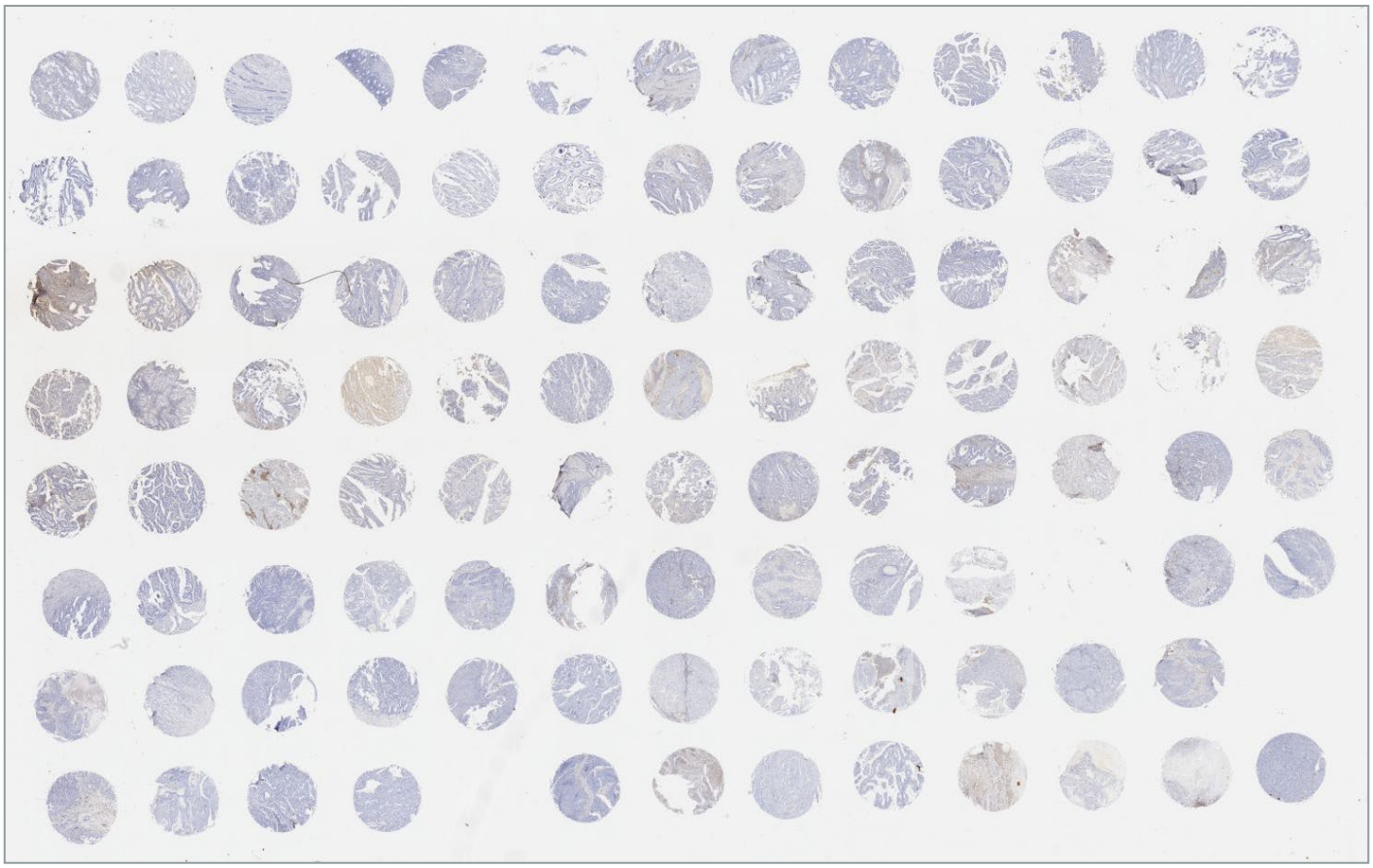

Figure 7

VISTA expression in endometrial cancer. IHC staining of a human endometrial cancer TMA (Pantomics #EMC1021), using anti-VISTA (ab230950) at a final concentration of 0.5 µg/mL. Pathological endometrial cancer subtypes included within TMA; normal (5 cases), adenocarcinoma (90 cases), adenosquamous carcinoma (4 cases), undifferentiated carcinoma (3 cases). Positive staining in brown; hematoxylin counterstain in blue. Magnification, x0.6.

AB0266_v2.0_090525

Representative IHC images of endometrial cancer TMA

Adenocarcinoma (2+)

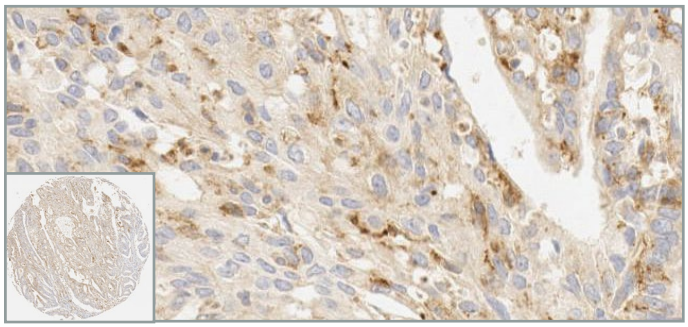

Adenocarcinoma (1+)

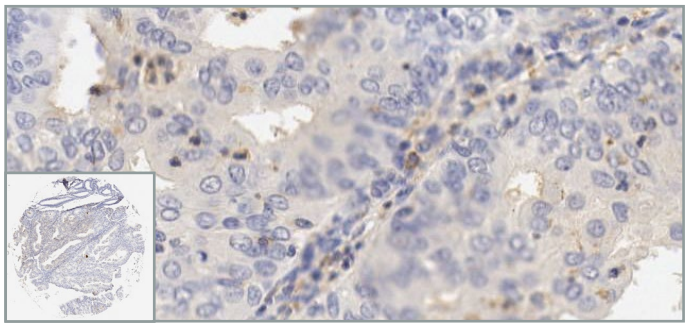

Adenocarcinoma (0.5+)

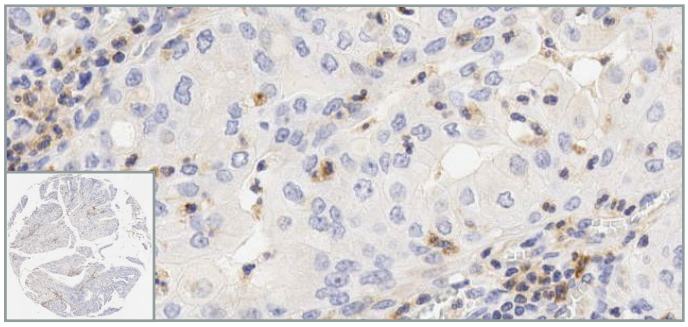

Adenocarcinoma (0+)

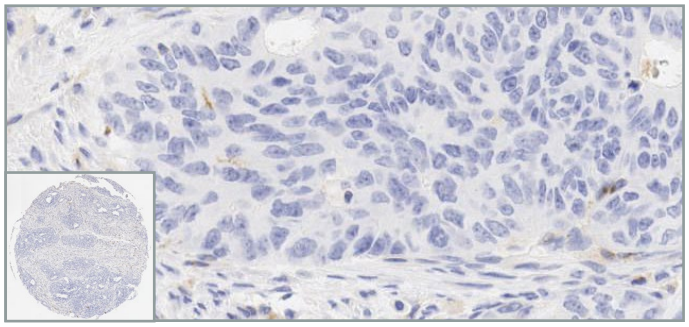

Adenosquamous carcinoma (2+)

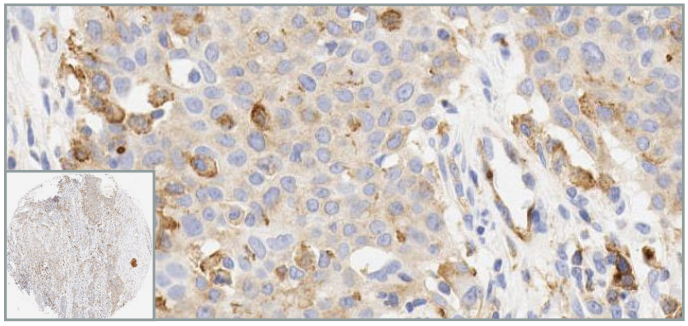

Adenosquamous carcinoma (0+)

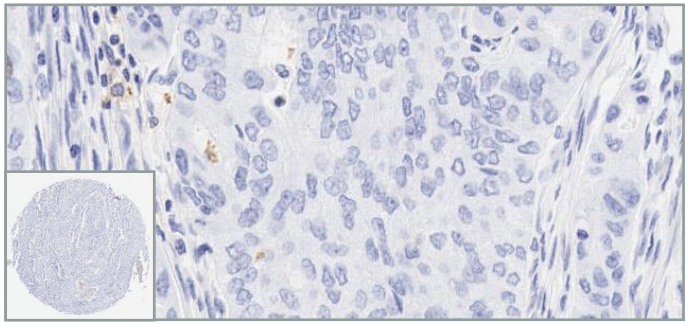

Undifferentiated carcinoma (0)

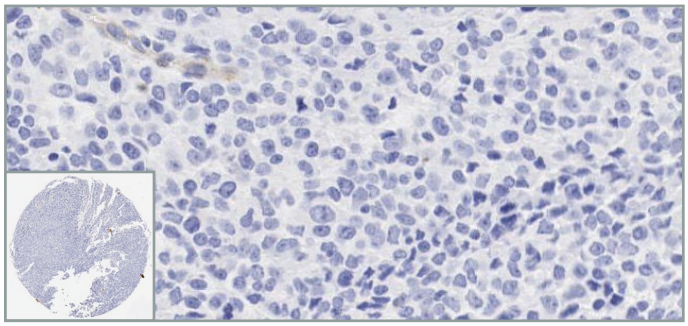

Figure 8

VISTA expression intensity in endometrial cancer. Semi-quantitative scoring of the average tumor expression intensity (0-3+, with a 0.5 interval) was performed by eye. Representative images show VISTA expression intensity observed in each pathological cancer subtype. Positive staining in brown; hematoxylin counterstain in blue. Magnification, x5 and x20.

AB0266_v2.0_090525

Liver cancer TMA

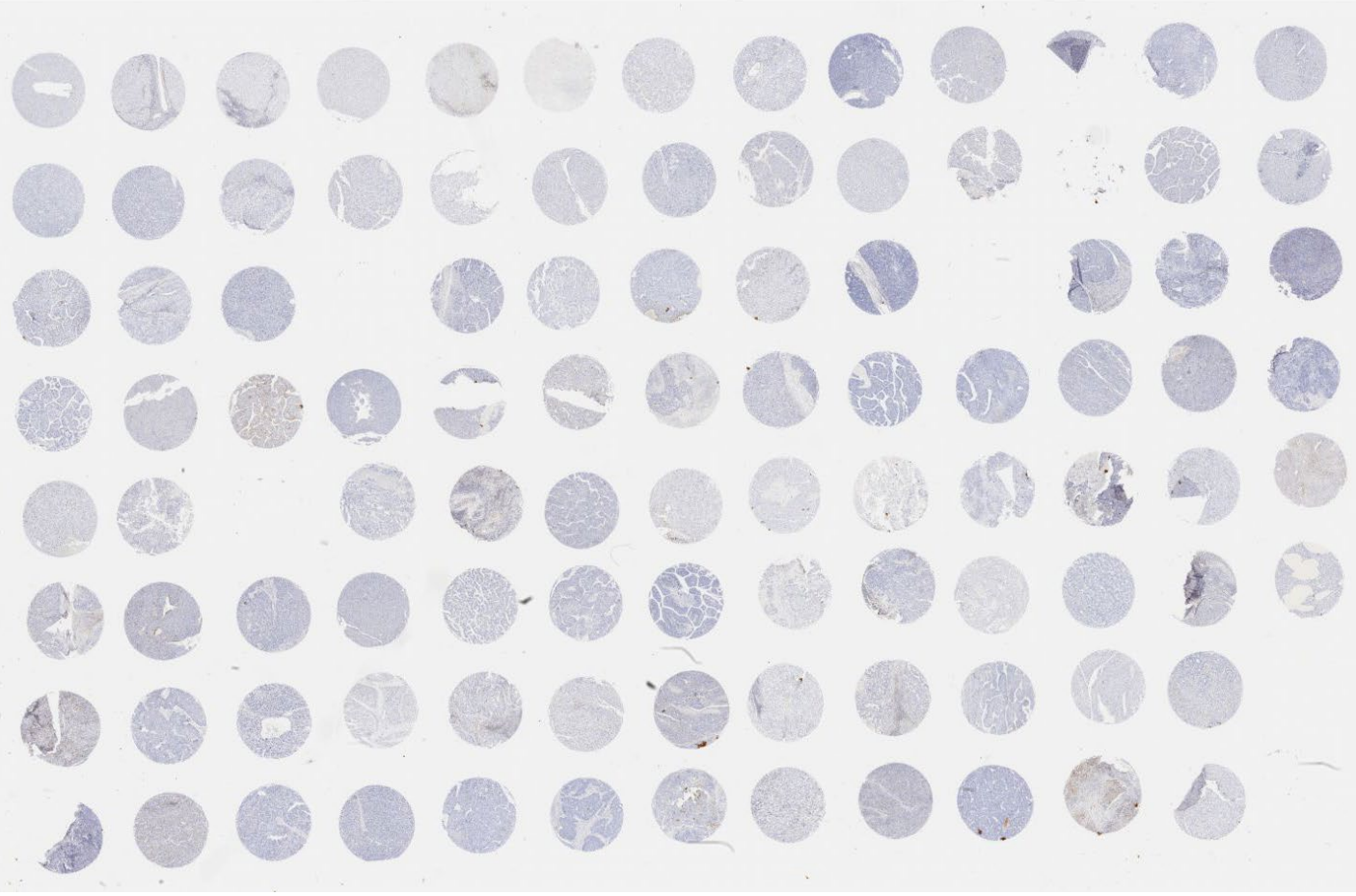

Figure 9

VISTA expression in liver cancer. IHC staining of a human liver cancer TMA (Pantomics #LVC1021), using anti-VISTA (ab230950) at a final concentration of 0.5 µg/mL. Pathological liver cancer subtypes included within TMA; normal (1 case), cholangiocarcinoma (2 cases), hepatocellular carcinoma (94 cases), mixed cholangiocarcinoma and hepatocellular carcinoma (1 case), viral hepatitis-related cirrhosis (1 case). Positive staining in brown; hematoxylin counterstain in blue. Magnification, x0.6.

AB0266_v2.0_090525

Representative IHC images of liver cancer TMA

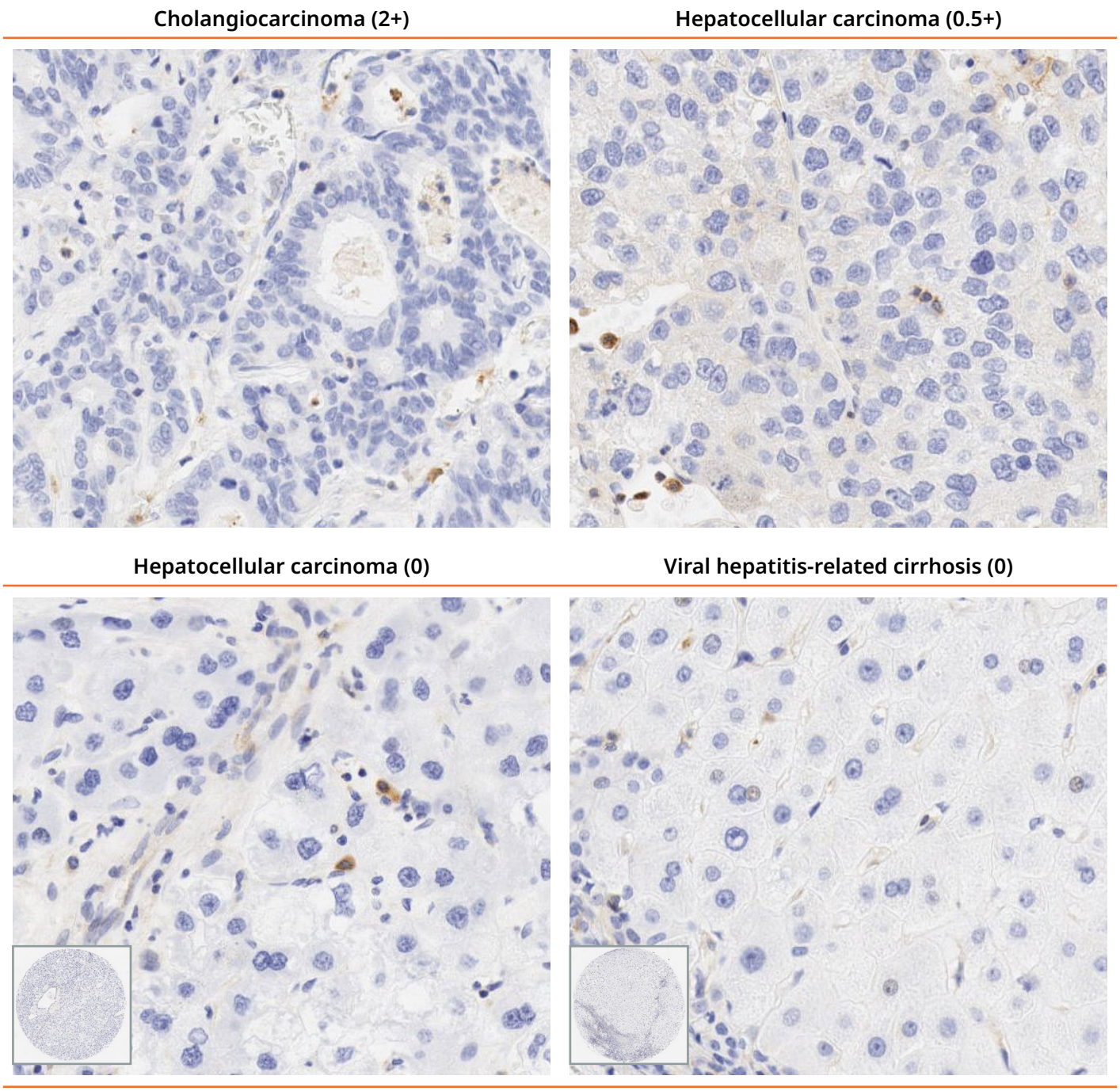

Figure 10

VISTA expression intensity in liver cancer. Semi-quantitative scoring of the average tumor expression intensity (0-3+, with a 0.5 interval) was performed by eye. Representative images show VISTA expression intensity observed in each pathological cancer subtype. Positive staining in brown; hematoxylin counterstain in blue. Magnification, x5 and x20.

AB0266_v2.0_090525

Cancer TMA whole core image analysis

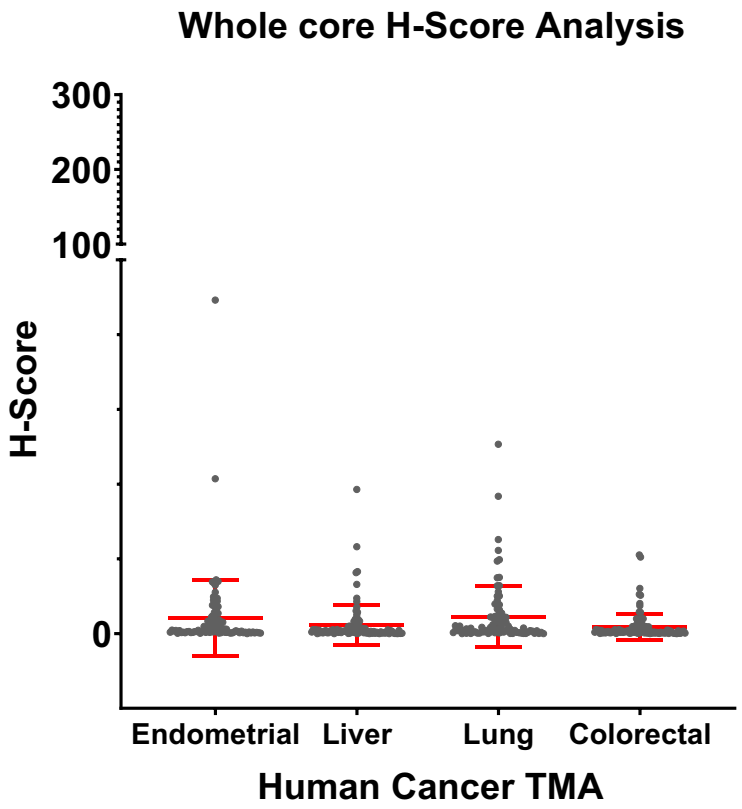

Figure 11

Cancer TMA whole core H-score analysis. Image analysis was conducted with QuPath v0.2.3 software using in-built analysis algorithms. Whole core analysis was performed by counting all negative and positive cells and separating positivity into 1+, 2+ and 3+ positivity. A combined H-score was created for each core. Liver (5/102), Lung (11/102) and Colorectal (1/102) and cores were excluded due to technical artefact.

AB0266_v2.0_090525

Start innovating together:

For all technical or commercial enquiries please go to:

www.abcam.com/contactus

www.abcam.cn/contactus (China)

www.abcam.co.jp/contactus (Japan)

www.abcam.com

Copyright © 2025 Abcam. All Rights Reserved. The Abcam logo is a registered trademark.
All information / detail is correct at time of going to print.

danaher